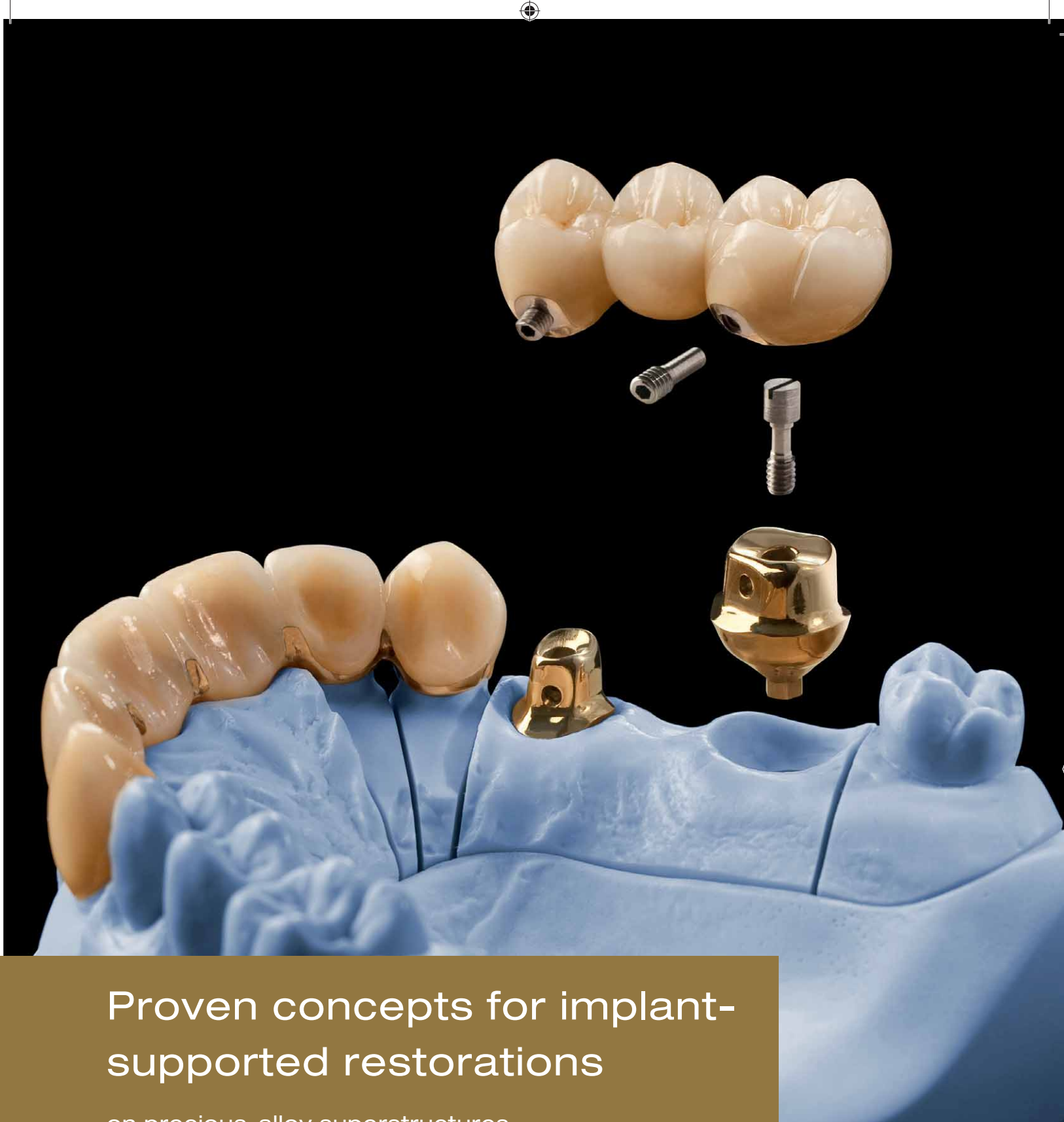

Proven concepts for implant-supported restorations

on precious-alloy superstructures

A guide for the dental office and the dental laboratory



CREDITS

*Sven Rinke, Dr. med. dent., M. Sc.
Hanau, Klein Auheim*

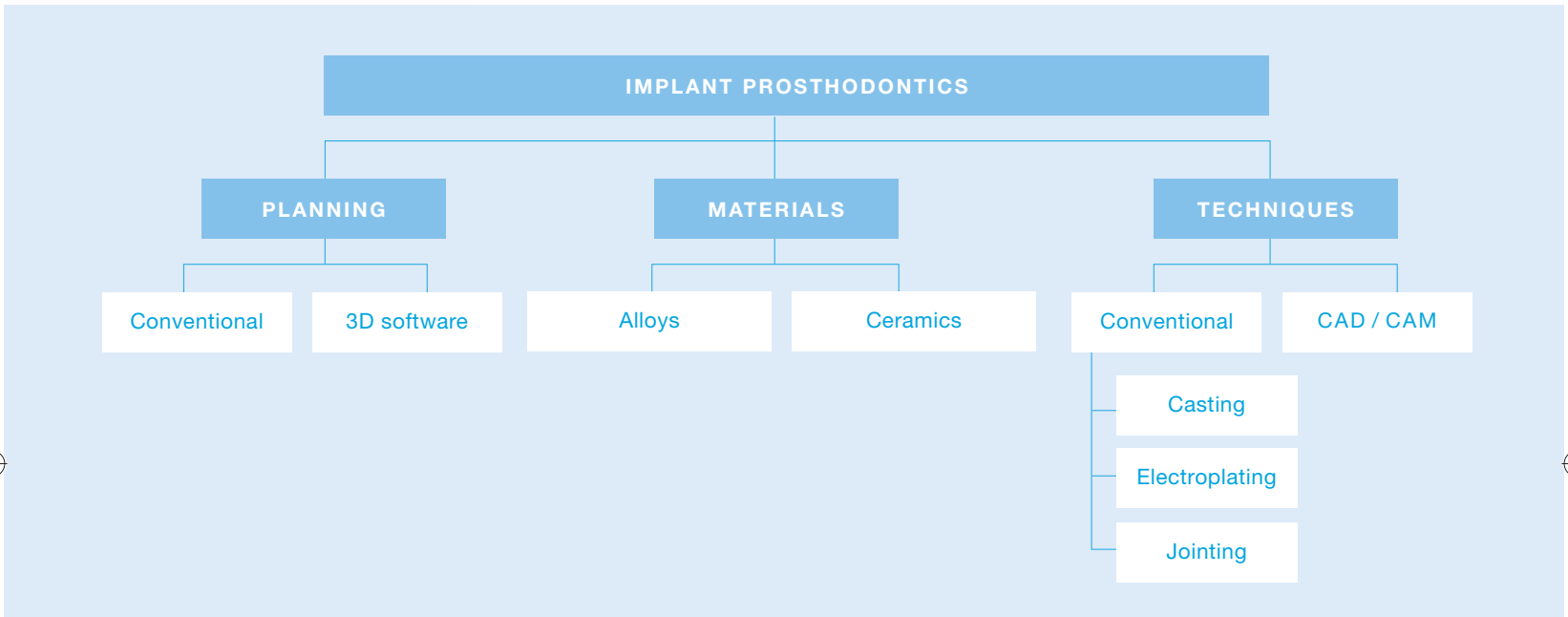
Cover image: Stefan Schalansky, MDT

Table of Contents

Implant prosthodontics today	5
Proven concepts for implant-supported restorations on precious-alloy superstructures	5
Pre-implantological diagnostics and planning for implant-supported crowns and bridges	6
Conventional treatment planning – Dental office and laboratory procedures	6
3D treatment planning – Dental office and laboratory procedures	8
Fixed superstructures in the partially edentulous jaw	10
A proven standard: Fixed superstructures made from dental alloys	10
Requirements related to prosthetic materials	10
Special laboratory aspects of fixed superstructures	12
Concept No. 1: <i>Implant-supported single crowns</i>	14
Concept No. 2: <i>Strictly implant-supported bridge</i>	14
Concept No. 3: <i>Combination bridge</i>	15
Advantages and disadvantages of different connection types	16
Fixed superstructures – Dental office and laboratory procedures	17
Restoring the edentulous jaw with removable and fixed restorations	18
Removable and fixed restorative designs	18
Attachment-related requirements	18
Mandible	20
Maxilla	22
Removable implant-supported restorations in the partially edentulous jaw	24
Conclusion	25
Removable superstructures – Dental office and laboratory procedures	26



Implant prosthodontics today





Proven concepts for implant-supported restorations on precious-alloy superstructures

Implant-supported restorations have become a scientifically recognized and indispensable part of today's armamentarium of treatment concepts. The fabrication of fixed or removable superstructures usually involves dental alloys conventionally processed by casting. Materials based on precious alloys offer many advantages in this respect: a broad range of indications, decades of documented and reliable clinical success, excellent biocompatibility and safe processing at the dental laboratory.

Innovative CAD/CAM technologies have opened new horizons for all-ceramic materials such as zirconia. Initial clinical results have shown that CAD/CAM-produced zirconia superstructures can be successfully employed for single crowns and shorter bridges. In addition, CAD/CAM facilitates the fabrication of customized zirconia abutments. Computer-assisted milling also allows the processing of metals that are difficult to cast in the dental laboratory (such as pure titanium), and that with impressive precision. Hence, CAD/CAM has already become a useful complement to the established modality of producing superstructures by casting. The use of dental alloys and compatible ceramic veneering materials in conjunction with suitable jointing techniques will continue to be the standard procedure for fabricating implant-supported restorations in the dental laboratory for the foreseeable future.

The keys for successful implant-supported restorations are carefully devised prosthetically driven pre-implant treatment planning. A minimally traumatic surgical procedure and a superstructure that ensures many years of function without complications.

Clinical long-term studies have documented high success rates for dental implants. Recent studies have shown that complications during function mainly originate with the superstructure. Implant-specific complications occur at the implant/abutment interface (screw loosening or fracture) or in the form of technical complications (ceramic chipping, loss of retention or material fracture). The clinician and dental technician together are faced with the challenge of offering the patient the most promising solutions and concepts.

Next to the treatment concept for implant-supported restorations, the importance of the suitability of the materials for the specific purpose should not be underestimated. The precision of fit must

be higher than for restorations on natural abutments, as osseointegrated implants exhibit no physiological mobility. Restorations that can be removed by the clinician or by the patient additionally require prefabricated prosthetic elements (attachments, bars) or custom-designed and individually fabricated retentive elements (telescope crowns). In addition, the use of jointing techniques such as laser-welding, soldering or adhesive bonding will often be necessary, at least in the case of more complex superstructures.

The present guide addresses clinical and laboratory issues related to fixed or removable implant-supported restorations with special emphasis on the choice of appropriate materials and material combinations (metal ceramics/jointing techniques). Numerous photographs and diagrams illustrate the procedures and offer workflow guidance for the implant/prosthodontic team in the dental office and the laboratory.

Pre-implantological diagnostics and planning for implant-supported crowns and bridges

Conventional treatment planning



Pre-implantological diagnostics supplements the usual clinical procedures (visual inspection, dental and periodontal status, functional diagnostics) by offering special techniques for the examination and evaluation of the soft-tissue and hard-tissue supply at the implant sites. Orthopantomographs (OPG) with calibrated measuring points are the most basic form of documentation in examining the vertical bone supply; where appropriate, they can be supported by other radiological projections. The horizontal bone supply is determined by making intraoral measurements of mucosal thickness, then transferring the resulting data to appropriate casts.

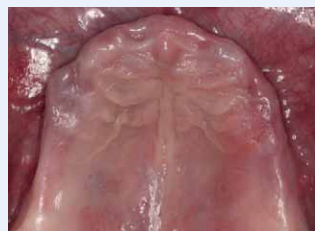

The restorative goal should be defined before proceeding to the implant insertion step. Diagnostic casts mounted in a semi-adjustable articulator form the basis for the diagnostic tooth set-up,

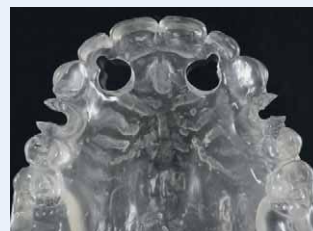which also helps determine the number of implants required and the most appropriate positions. These positions should be intraoperatively transferred to the oral environment using laboratory-produced surgical or drilling stents fabricated in close cooperation between the clinician and dental technician.

Diagnostic simulations help define the best positions and inclinations for the emergence profile of the implant-supported restorations. They also provide information on possible deficiencies of the hard and soft peri-implant tissues, allowing necessary corrections to be made in time (such as changes in treatment planning or bone augmentation procedures).

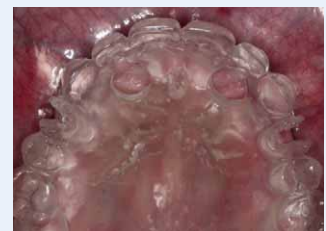CLINICAL EXAMPLE



Baseline situation of an edentulous maxilla to receive four implants.



Fabrication of a surgical stent to define the positions of the four implants.



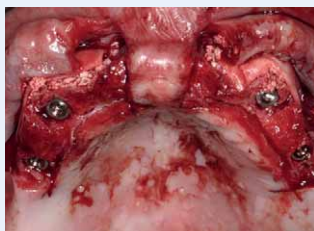
The surgical stent in situ.



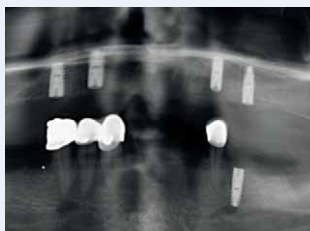
Dental office and laboratory procedures

Conventional implant insertion requires the following steps to be performed in the dental office and at the laboratory:

Time to next appointment	Appointment 1	Approx. 3–5 days	Approx. 3–5 days	Appointment 2
DENTAL OFFICE	Diagnostic impressions, x-rays, diagnostics, bite registration			Implant insertion
DENTAL OFFICE AND LABORATORY	Definition of the prosthetic treatment outcome		Discussion of the wax-up	Placement of the laterally open pilot drilling holes
LABORATORY		Mounting and wax-up	Duplication of the wax up, fabrication of a surgical stent in transparent acrylic	

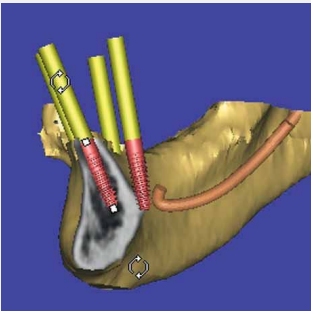


Intraoperative situation during the insertion of four implants in the edentulous maxilla.



Control OPG after implant insertion.

3D planning



3D implant planning using the Simplant software.

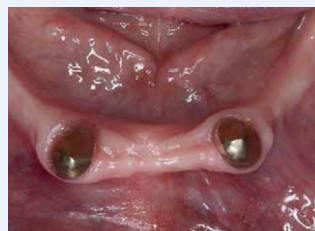For special indications, the bone situation can be visualized using computed tomography (CT) or cone-beam computed tomography (CBCT) technology. The evaluation of the bone supply based on three-dimensional images may lay in the foundation for the planning and surgical stents.

The prosthetic treatment outcome should already be defined and simulated by a wax-up prior to performing 3D diagnostics. The wax-up, together with a so-called scanning template made of radiopaque resin, will be included on the three-dimensional CT or CBCT image. During the virtual planning stages, it will serve as reference for the prosthetically driven implant placement.

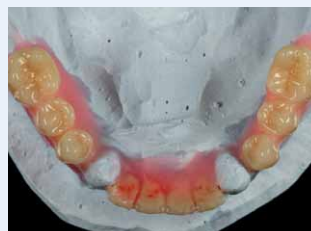BENEFITS

- + 3D planning software (e.g. Expertease, Friadent, Mannheim, Germany) facilitates exact three-dimensional implant planning based on CT or CBCT data
- + The planning can be transferred to the mouth intraoperatively using stereolithographic stents
- + The surgical stent may be supported by teeth, bone or mucosa
- + Accurate transfer of implant positions and shorter surgical procedures
- + Reduced surgical trauma (flapless surgery)

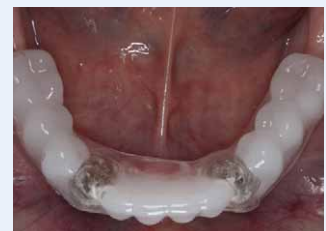CLINICAL EXAMPLE



Baseline situation for a planned rehabilitation involving four maxillary intraforaminal implants.



Wax-up for fabricating a scanning template.



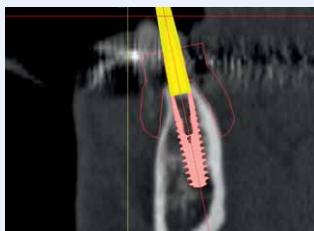
Inserted scanning template with radiopaque teeth made of resin containing barium sulphate.



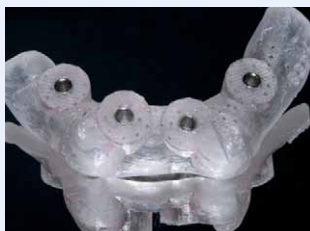Dental office and laboratory procedures

Implant insertion supported by 3D software requires the following steps to be performed in the dental office and at the laboratory:

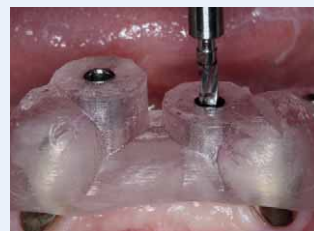Time to next appointment	Appointment 1	Approx. 3–5 days	Approx. 3–5 days	Appointment 2	Approx. 12–14 days	Termin 3
DENTAL OFFICE	Diagnostic impressions, bite registration (radiological diagnostics)			3D diagnostics with scanning template inserted; referral to radiologist if required		Implant insertion
DENTAL OFFICE AND LABORATORY	Definition of the prosthetic treatment outcome		Discussion of the wax-up		Virtual planning using Expertease software; ordering the surgical stent	
LABORATORY		Mounting and wax-up		Production of the scanning template		



Implant position, transversal section.



Stereolithographic drilling stent (Materialise, Leuven, Belgium).



Minimally invasive implant insertion with tooth-supported drilling stent.

A proven standard: Fixed superstructures made from dental alloys

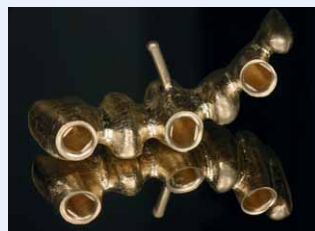Despite substantial progress in the field of all-ceramic materials, precious dental alloys continue to be the standard for fixed implant superstructures. The choice of alloy is determined by its area of application and by its technical specifications. Simple and safe processing in the laboratory, however, is also an important aspect. As always in prosthodontics, only biocompatible and corrosion-resistant materials can be used. Finally, financial and forensic aspects also influence the choice of material.

Requirements related to prosthetic materials

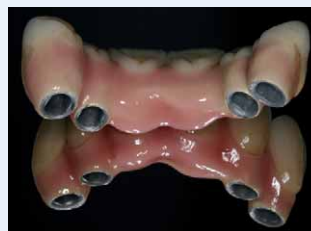- By contrast with natural teeth, osseointegrated implants exhibit no physiological mobility whatsoever. For this reason, alloys used for implant superstructures must have high distortion resistance.
- Complex superstructures, often with screws and design-mandated segmentation, may exhibit gaps, so the alloys use must meet very high demands in terms of corrosion resistance and colour stability. Industrially prefabricated components are often included that can be customized by a cast-to process. Hence, dental alloys for superstructures should ensure good cast-to results.
- Compared to natural abutments, the frameworks must build up to reinforced anatomic contours.
- Implant superstructure design sometimes mandates segmentation, with the different segments been connected by screws or precision attachments. For this reason, the alloys use must possess good milling properties.
- Ideally, superstructures should be realized as one-piece castings. This should be facilitated by a suitable combination of modelling materials, investment compounds, alloys and casting techniques. Soldering should be reduced to a minimum. To meet these requirements, the materials used should constitute an excellent match.
- In addition, the absence of a physiological damping effect results in higher demands of the stability of the ceramic veneer.



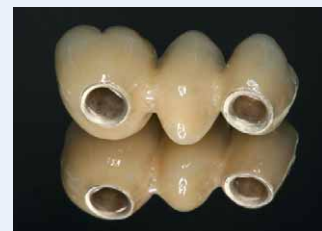EXAMPLES



Six-unit implant-supported superstructure made of Degunorm supra.



Ceramically veneered superstructure made of Degupal G.



Ceramically veneered superstructure made of Degunorm supra.



Selecting the right precious alloy

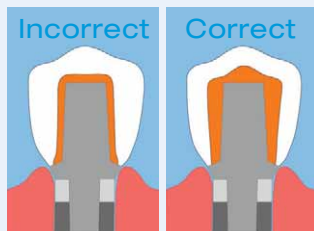
Precious dental alloys are particularly well suited for fabricating implant superstructures thanks to the many years of experience with these mature and technologically safe materials. In addition to excellent biocompatibility, these alloys also offer a high level of ceramic veneer stability. Precious dental alloys can be joined by soldering, by laser welding or adhesively. Provided the right alloys are chosen,

cast-to and milling are also supported. This combination of properties is ideal for implant superstructures for all indications.

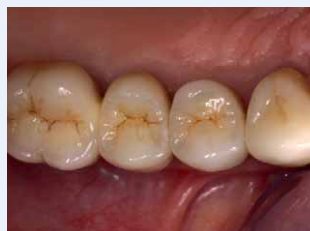Of the great variety of available dental alloys, a group of three has been chosen that ideally meet all the above-named requirements*:

	DEGUDENT H	DEGUPAL G*	DEGUNORM SUPRA	BENEFITS
Alloy type	Gold-based	Palladium-based	Gold-based	<ul style="list-style-type: none"> + Excellent mechanical properties, Type IV alloy, extra hard, yield strength > 400 N/mm²; elongation at fracture > 5% (achievable values after ceramic veneering) + Excellent high-temperatures stability (distortion resistance) + Excellent corrosion resistance + Excellent colour stability + Good jointing properties (soldering, laser-welding, adhesive bonding) + Good milling properties + Excellent veneering safety + Simple and safe processing + Excellent biocompatibility
Veneer	High-melting (Duceram Kiss, Duceram Love)	High-melting (Duceram Kiss, Duceram Love)	Low-melting (Duceragold Kiss)	
Soldering before firing	Degudent solder N1	Degudent solders G1, N1	Degunorm solders 880, 930 BiOcclus solder G 870	
Soldering after firing	Unilot 2 Degulor solder 2	Stabilor solder 710 Degulor solder 2	Degunorm solder 700 BiOcclus solder G 710	
Laser welding wire	Available	Available	–	
Composition in mass %	Au: 84.4 Pt: 8.0 Pd: 5.0 In: 2.5 Ta: 0.1	Au: 4.5 Pd: 77.3 Ag: 7.2 Sn: 4.0 Ru: 0.5 Ga: 6.0 Ge: 0.5	Au: 73.2 Pt: 3.2 Pd: 6.3 Ag: 13.8 Sn: 0.5 Zn: 2.9 Ir: 0.1	

* The melting range of the prefabricated components must be high enough to preclude melting by contact with the molten alloy



Graphic representation of the framework build-up to reinforced anatomic contours.



Implant-supported single-crown restoration (Degunorm supra with Duceragold Kiss).

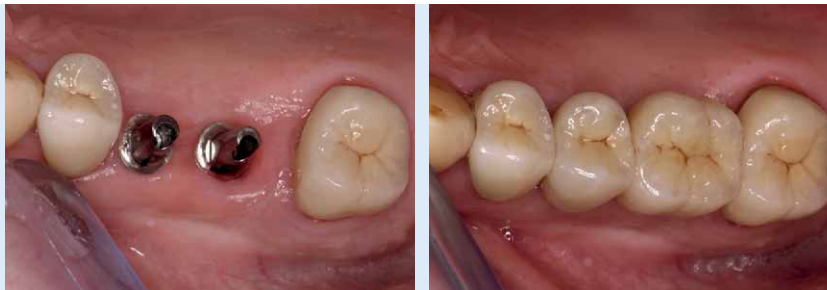Fixed superstructures in the partially edentulous jaw

Special laboratory aspects of fixed superstructures

If an indication for implant-supported restorations exists, the fixed superstructure may follow one of these three concepts:

CONCEPT NO. 1 Implant-supported single crowns

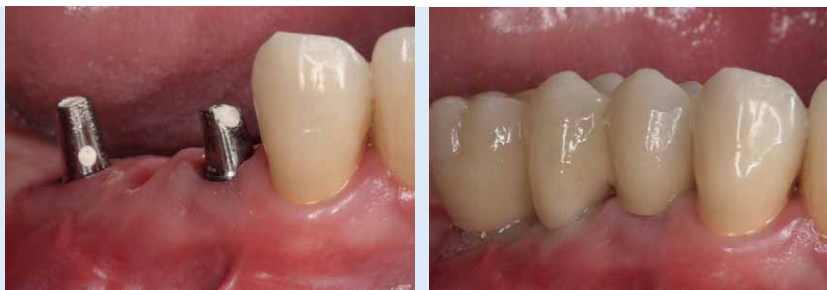1



Two implant-supported maxillary single crowns.

CONCEPT NO. 2 Strictly implant-supported bridge

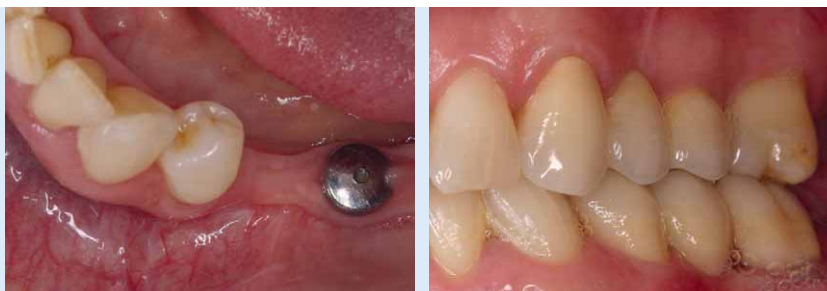2



Implants at sites 24 and 26 to support the cemented bridge.

CONCEPT NO. 3 Combination bridge

3




Three-unit cemented superstructure made of Degudent H



Strictly implant-supported bridges/ single crowns are indicated especially in patients with:

- An adequate bone supply
- Healthy tooth substance
- Periodontally or endodontically compromised distal natural tooth
- Strictly implant-supported designs are particularly advisable when the distal-most tooth does not appear to require treatment at the time of the treatment planning.



Generally, **combination bridges** should be designed as three-unit bridges. When providing a combination tooth-/implant-supported bridge, bridges with rigid connectors using screw-secured attachments or one-piece bridge designs that can be cemented should be preferred over mobile connectors (interlocks, resilient attachments).

When selecting a treatment approach, the greatest importance should be attached to the horizontal and vertical bone supply. In addition, the following factors should be critically examined:

- Suitability of the abutment teeth on both sides of the edentulous (endodontic treatment, periodontal disease, missing hard tissue)
- Required width of the restorative design
- Possibly required prosthetic restoration of antagonists
- Periodontal status of the antagonists

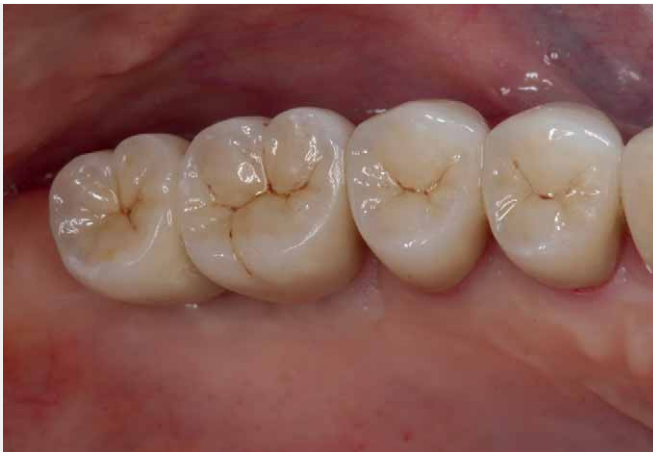Fixed superstructures in the partially edentulous jaw

1 + 2

CONCEPT NO. 1 UND NO. 2

Strictly implant-supported bridges and single crowns

Cemented single crowns on two implants at sites 26 and 27.



BENEFITS

- + Independent restoration, which is beneficial e.g. when repairs are required
- + Cemented restoration without restricting control access
- + Protection of natural tooth tissue
- + Preservation of the alveolar ridge due to continued functional loads
- + Easy to perform peri-implant hygiene (Concept No. 1)

Both implant-supported bridges and single crowns can be produced. Bridges are indicated if all teeth cannot be replaced with an implant (e.g. if the bone supply is insufficient). Single-tooth implants are indicated especially where only one tooth is to be replaced. Primary splinting of single crowns can be considered if the length ratio between the

clinical crown and the dental implant is unfavourable or if high masticatory forces are expected (e.g. in the molar region). A rehabilitation using single-tooth implants in the posterior region is particularly challenging in terms of implant design. Implants with sufficiently stable anti-rotational mechanisms should be preferred.

PRACTICAL NOTES

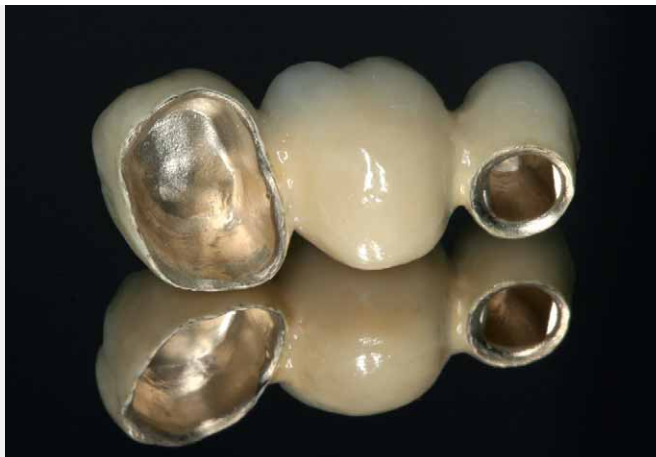From an aesthetic and phonetic point of view, restoring two or more adjacent anterior teeth with single-tooth implants is particularly difficult.

To achieve the best treatment result, implants must be placed very accurately and to exactly the right depth. It will not always be possible to ensure appropriate growth of the interdental papilla between two implants. This is an aesthetic limitation to be taken into account when considering indications.

3

CONCEPT NO. 3

Combination bridges



BENEFITS

- + Reduced number of implants
- + Lower surgical risk (augmentation procedures are avoided)

Three-unit combination bridge made of Degunorm supra, conventionally cemented.

Combined tooth/implant-supported fixed bridges (combination bridges) should be considered as a prosthetic alternative in the treatment of partial edentulism if:

- The distal abutment exhibits hard-tissue damage (indication for prosthetic treatment or teeth already carrying a crown restoration).
- The distal abutment exhibits no periodontal damage (mobility).
- The bone supply in the immediate vicinity of the tooth is insufficient for inserting implants.
- Financial considerations play a paramount role.

In this way, any intrusion of the natural tooth relative to the implant-supported aspect of the bridge can be prevented. Independently of the bridge design, definitive cementing on the natural abutments is recommended to prevent long-term retention loss and secondary caries. Endodontically treated abutments are suitable for supporting combination bridges only in certain narrowly circumscribed cases. Consequently, this approach should be considered only if strict indication exists. To minimize the fracture risk, the tooth should be restored with a post-and core before being considered as a bridge abutment.

CLINICAL EXAMPLE



Graphic representation of a combination bridge design.



Working cast for the fabrication of a three-unit combination bridge.

Fixed superstructures in the partially edentulous jaw

Advantages and disadvantages of different connection types



Implant-supported fixed superstructures can be either screw-retained (with occlusal or transversal screws) or cemented. Both these connection modes have their clinical benefits and shortcomings, which should be carefully evaluated based on the specifics of each particular case. One-piece superstructures (single crowns or three-unit bridges) can be definitively cemented using a zinc phosphate or glass-ionomer cement. Temporary cementing makes the restoration removable to a limited extent. Due to the lower bond strength of conventional temporary zinc oxide cements, abutments should be sufficiently high and present with a roughened surface to improve retention (sandblasting, grinding with diamond instruments). The crown margin should be fully accessible for the complete removal of excess cement.

Joining techniques

In fixed prosthodontics, the use of joining techniques should be reduced to a minimum. Frameworks should preferably be cast in one piece. The following joining techniques can be considered:

- **SOLDERING**
- **LASER WELDING**

Connecting two objects made of the same type of material by soldering using corrosion-resistance solders is not problematic, provided the soldering is performed properly. Alternatively, laser welding may be performed using alloy-specific laser welding wires.

Screw-retained superstructures

BENEFITS	<ul style="list-style-type: none"> + (Limited) removability + Repairable + Connection as possible even if the occlusal clearance is low (transversal screws)
SHORT-COMINGS	<ul style="list-style-type: none"> - Occlusal screw access holds may impair aesthetics - Potential screw loosening or fracture (single crowns) - Potential local stress peaks caused by retention screws

Cemented superstructures

+ Simple handling and fabrication
+ Smaller gaps
+ Uninterrupted occlusal surface improved aesthetics
- Not removable without damaging the construction




Dental office and laboratory procedures

Optimize workflow from impression and bite registration to delivery


Timeline	Appointment 1	Approx. 3–5 days	Appointment 2	Approx. 5–10 days	Appointment 3	Approx. 5–10 days	Appointment 4
DENTAL OFFICE	Exposure Diagnostic impressions		Impressions Bite registration Shade taking		Framework try-in (bite registration)		Delivery of restoration
IMPLANT LOGISTICS		Ordering implant components for impression		Ordering implant components for build-up and screw retention			
LABORATORY		Fabrication of custom impression trays		Cast fabrication, customization, build-up, framework fabrication		Ceramic veneering	

The timeline between appointments is based on the calculated times for single crown and bridge restorations. In the case of patients receiving multiple restorations, the timeline may be modified by consultation with the laboratory. Compared to conventional prosthetics, extra time should be allowed for sourcing and preparing the implant components prior to fabricating the restoration proper.


EXAMPLES



Implant-supported crowns, laterally screw-retained.



Roughening and abutment by sandblasting to improve retention.



Alternative technique for intraoral abutment roughening using a diamond cutter.

Restoring the edentulous jaw with removable and fixed restorations

Removable and fixed restorative designs

Precious dental alloys also constitute an important material foundation for the fabrication of removable superstructures. However, various removable superstructures designs are associated with different requirements.

Attachment-related requirements

Different attachment designs may be used, such as bar designs employing prefabricated components, custom-milled bar attachments or telescope crowns. All these should be highly wear-resistant to preclude early retention loss.

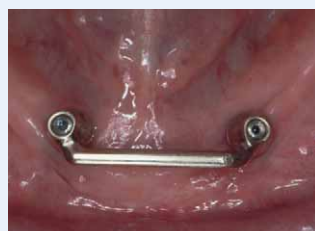In addition, designs cast in one piece (bar attachments or telescope crowns) must allow simple and safe milling. The gaps between the primary and secondary components, which are unavoidable for principal reasons, increases the risk of

corrosion and discolouration that must be minimized by working with a resistant material with good processing properties.

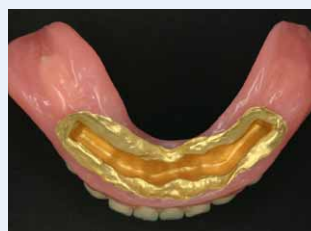With removable restorative designs, the choice of the right jointing technique is essential because jointing itself cannot be avoided in the vast majority of cases. Adhesive techniques or laser welding should be preferred especially when joining components of different material types (such as precious and non-precious alloys).



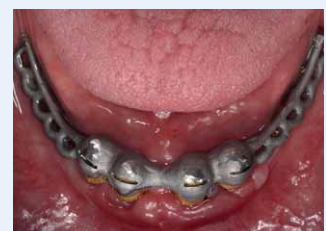EXAMPLES





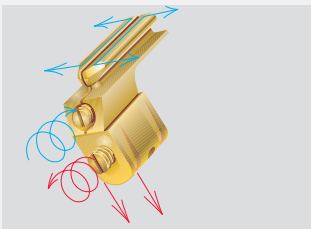
Bar supported by two implants, made of prefabricated Degunorm components.



Electroplated secondary crowns (Solaris system, DeguDent).



Reinforcing metal framework for an implant-supported overdenture made of the Biosil I CoCr alloy.



In the case of removable superstructures, therefore, the selection of the materials is supplemented by the following components and techniques:

- Pre-fabricated components such as Degunorm bar profiles and sleeves connected by soldering or laser welding.
- Electroplated secondary components for bar attachments or telescope crowns; both these indications are covered by the Solaris electroplating system.
- Cobalt-based alloys with a high modulus of elasticity for reinforcing the denture base. Ideally, these materials should be joinable both adhesively and by laser welding.

These requirements are ideally met by Biosil I, a non-precious alloy. In principle, all implant-supported designs should feature a metal framework for added stability.

In addition, prefabricated attachments or retention elements can be used for specific indications. These components can be cast to one of the three recommended dental alloys:

- Degudent H
- Degupal G*
- Degunorm supra

provided that the specific properties of the materials are taken into due account.

(top)
multi-CON, intracoronal attachment

(centre)
multiSafe bar, extra coronal connective, retention and support element

(bottom)
GGS bar system

* The melting range of the prefabricated components must be sufficiently high to preclude melting by contact with the molten alloy.

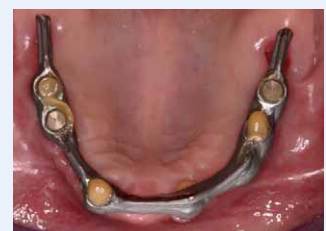EXAMPLES



Soldering



Laser welding

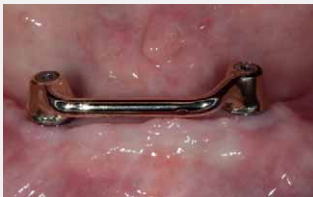

Adhesive connection

Restoring the edentulous jaw with removable and fixed restorations

Mandible

The atrophied edentulous jaw – especially if it is a mandible – is considered the classical indication for implant-retained dentures. Here, implant support is to be considered an absolute indication in patients with insufficient mandibular denture retention. From a prosthetic point of view, the number of implants determines the choice of superstructure design. Implant-supported restorations for the edentulous mandible can be classified as follows:



Bar attachment made of prefabricated Degunorm components.

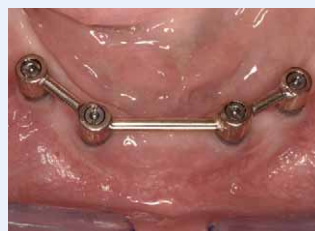Two implants

The basic design type is the insertion of two intraforaminal implants (usually in the canine region). The superstructure can be a bar with a round or ovoid cross-section. To give the overdenture sufficient horizontal guidance, the implants should be spaced at least 20 mm apart. The bar should preferably be fabricated using pre-fabricated components made of precious dental alloys (such as Degunorm). Telescope crowns can also be used when two implants are inserted in the mandible. To avoid flexural stress, resilience support is preferred for the overdenture.

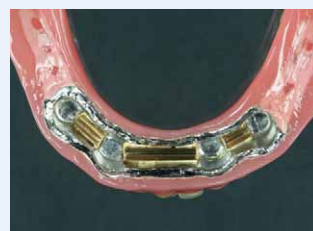Four implants

The insertion of four fairly evenly spaced intraforaminal implants is considered a standard design. The superstructure may be a round bar (prefabricated components) or a bar attachment (individually milled). Resting the bar on four implants offers good stability in the transversal and horizontal dimensions, virtually precluding any rotation. However, the price for this high stability is limited access for oral hygiene. For this reason, it is advisable to design the superstructure with perio-implantological aspects in mind. Bar superstructures permit immediate implant loading, provided that bone density is high, primary implant stability is sufficient and the implants are long enough.

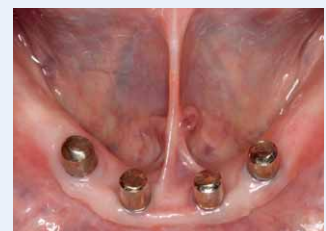CLINICAL EXAMPLE



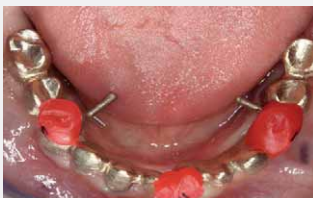Bar attachment on four implants, made of prefabricated Degunorm components.



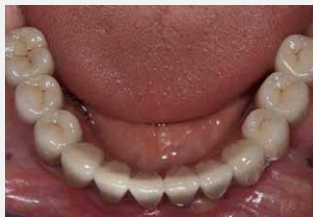Prefabricated Degunorm retention elements for a bar supported by four implants.



Milled Degunorm supra telescope crowns on four implants.



Bridge framework for a Degunorm supra fixed superstructure supported by six implants.



Ceramically veneered Degunorm supra bridge supported by six implants.

If support is provided by telescopic crowns, this also provides good horizontal and sagittal denture guidance. In addition, it allows the denture to be shaped similar to a bridge in the region between the implants, facilitating better oral hygiene.

Six to eight implants

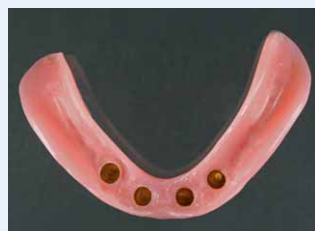Insertion of (usually) six implants in the horizontal region of the mandible with subsequent insertion of a removable or fixed strictly implant-supported bridge. For removable bridges, individually milled telescope crowns are preferred as attachments. The bridge framework is cast in one piece. Removable restorations are veneered in composite resin, while ceramics should be preferred for fixed restorations.

PRACTICAL NOTE

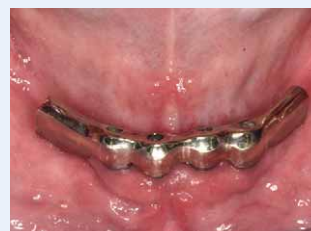To prevent fractures of the denture base, implant-supported overdentures should always be designed with a stabilizing metal framework. CoCr-based frameworks are particularly well suited for this purpose because of their compatible modulus of elasticity. Laser-weldable materials such as Biosil I should be given preference. Alternatively,

secondary and tertiary structures might be joined adhesively (with e.g. Degufill KE Gold, DeguDent).

Supporting metal frameworks should be dispensed with only in patients wearing a strictly gingivally supported denture in the opposing jaw.



Overdenture with electroplated secondary crowns (Solaris system, DeguDent).



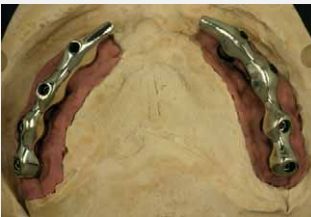Custom Degunorm supra bar attachment.

Restoring the edentulous jaw with removable and fixed restorations

Maxilla

When restoring the maxilla with implant-supported restorations, the different bone structure compared to the maxilla must be taken into account. Treatment concepts will be influenced particularly by the higher percentage of spongy bone. For this reason, a greater number of implants is usually thought to be required in the maxilla. Moreover, the biomechanical loading situation in the maxilla is influenced by centripetal atrophy, with the result that implants in the edentulous maxilla will often be tilted outward.

Four implants



Insertion of four implants in the anterior segment of the edentulous maxilla. The superstructure may be a round bar (prefabricated components) or a bar attachment (cast in one piece or individually milled). In overdentures, palatal coverage can be reduced.

An alternative to a bar is a design based on telescope crowns. Benefits and shortcomings are the same as in the mandible. Ball attachments will usually be contraindicated in the maxilla because of the implant divergences.

Six implants

Insertion of (normally) six implants evenly spread out across the maxillary alveolar ridge. Insertion of the distalmost implants usually requires a prior sinus lift procedure. Possible superstructures include a removable, strictly implant-supported overdenture without palatal coverage – or a bridge design. Telescope crowns may be used as an alternative to bar attachments. This concept allows the removable denture to aesthetically shape and support the facial soft tissues including the upper lip.

This design should be favoured in patients with plenty of vertical space or to maximize stability without palatal coverage.

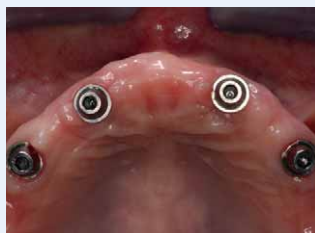Ball attachments

BENEFITS	+ Minimal space requirement
	+ Easy cleaning
SHORT-COMINGS	- Functional problems taking the form of tilting action of the mandibular denture: ensure parallelization of implants!

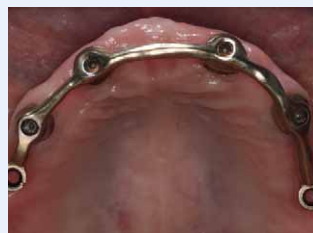Magnetic attachments

+ Minimal space requirement
+ Easy cleaning
- Reduce horizontal guidance potentially resulting in this patient acceptance

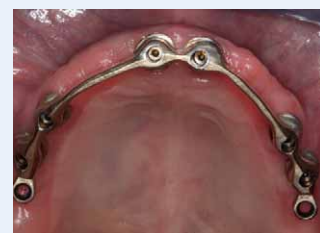CLINICAL EXAMPLE



Four implants in the maxillary anterior segment.



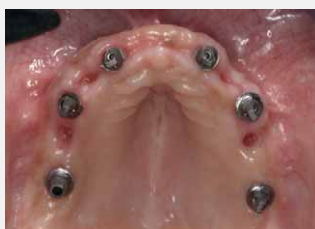Bar attachment on four implants to support an overdenture.



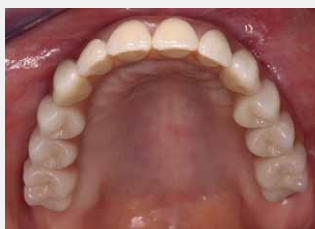Bar attachment made of Degunorm supra, on six implants.



Six to eight implants



Insertion of six to eight implants in the lateral segments of the maxillary alveolar ridge. Insertion of the implants and the premolar or molar regions will usually require a sinus lift. The central incisor sites are generally not used as implant sites, so that the maxillary anteriors can be restored in the manner of bridge pontic.



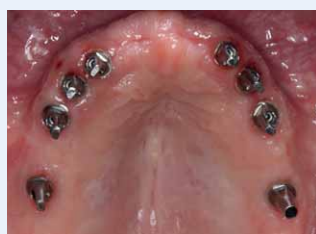The superstructure employs a bridge design or, if the patient exhibits extensive loss of the soft and hard tissues, an overdenture design, preferably retained by telescope crowns or bar attachments.

Six implants in the edentulous mandible and a fixed bridge restoration.

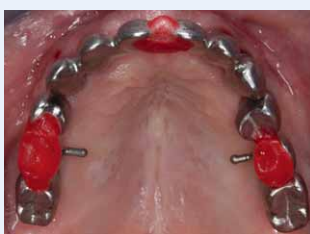PRACTICAL NOTE

Whether the restoration is fixed or removable, a try-in of the denture set-up should be performed using an implant-secured template prior to fabricating the framework, in order to verify the aesthetic and phonetic aspects of the restoration.

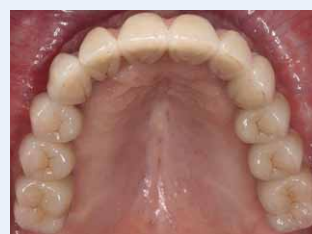Based on the layout mandated by the tooth set-up, the framework can then be optimally designed for the fixed or removable restoration.



Eight Ankylos implants (Dentsply Friadent, Mannheim, Germany) to support a fixed bridge.



Try-in of the three bridge framework segments (26-24/23, 22-12, 13/14-16) for the fixed restoration (frameworks made of Degupal G).



Ceramic veneered bridge design on eight maxillary implants.

Removable implant-supported restorations in the partially edentulous jaw

Removable implant-supported restorations in the partially edentulous jaw

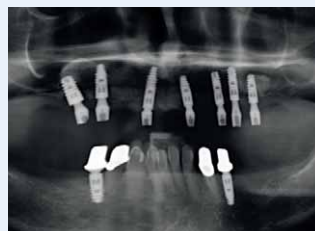A combination of implants and natural teeth supporting a removable restoration is indicated in patients with pronounced unilateral or bilateral partial edentulism or in patients with a seriously reduced dentition (one to three teeth remaining).

Implant-supported restorations in the presence of these indications are to improve the positional stability by providing additional retention elements at strategically favourable positions. The use of dental implants as strategic supplementary abutments is intended to prolong the life of the restoration and the residual teeth. Strategic supplementary abutments can be provided to restore the functionality of an existing denture or to provide

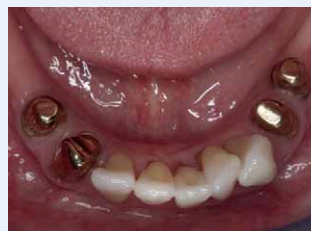a completely new restoration. The recommended retention elements are telescope crowns, because they make it easy to expand or modify the design of the restorations. Especially when the functionality of an existing denture is to be restored, the superstructure may be connected with ball attachments or retention cylinders. Bar attachments can also be used, although for these a strictly implant-supported design is preferred. Bars connecting natural teeth and implants should be screw-retained for easy removal by the practitioner in the event that the design has to be modified. The following recommendations can be given with regard to the number and positions of the strategic abutments:



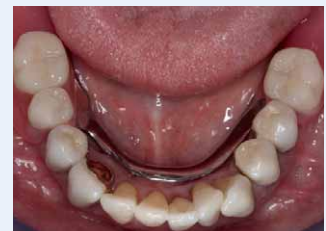EXAMPLES



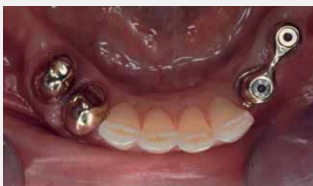Strategically increasing the number of available abutments by inserting two implants at sites 34 and 45.



Primary crowns for the natural teeth and Degunorm supra implants.



Implant-supported restoration resting on telescope crowns.

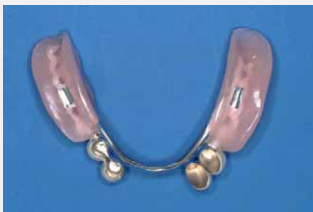

Providing a new restoration

Insertion of a sufficient number of implants in strategically favourable positions, such that, ideally, the restoration can still be worn as a strictly implant-supported restoration in the event that the natural abutments are lost:

- **MAXILLA: UP TO FOUR IMPLANTS**
- **MANDIBLE: TWO TO FOUR IMPLANTS**

Designs that can be easily extended should be preferred.



Strategically increasing the number of available abutments by inserting two implants at sites 33 and 34.

Restoring the functionality of an existing denture

Insertion of one to two implants in strategically favourable positions to expand the “support polygon” using easy-to-integrate retention elements (ball attachments, retention cylinders).

Both when providing a new restoration and when providing strategic supplementary abutments, the suitability of the existing natural abutments to be included should be evaluated very critically.

Conclusion

Implant-supported restorations will continue to play an ever greater part in prosthodontics. Precious dental alloys are suitable for many indications and are therefore used almost universally for implant superstructures.

Excellent documented clinical long-term results and safe processing are the foundation for long-lasting biocompatible restorations. Combined with

dental veneering ceramics, they also offer broad opportunities for giving implant-supported restorations and natural aesthetic appearance.

Implant superstructures based on precious dental alloys constitute the “gold standard” today; they are widely established and scientifically proven.



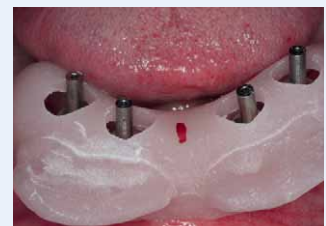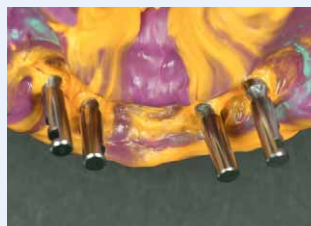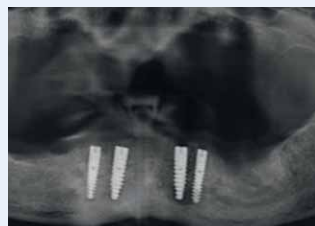
Removable implant-supported restorations
in the partially edentulous jaw

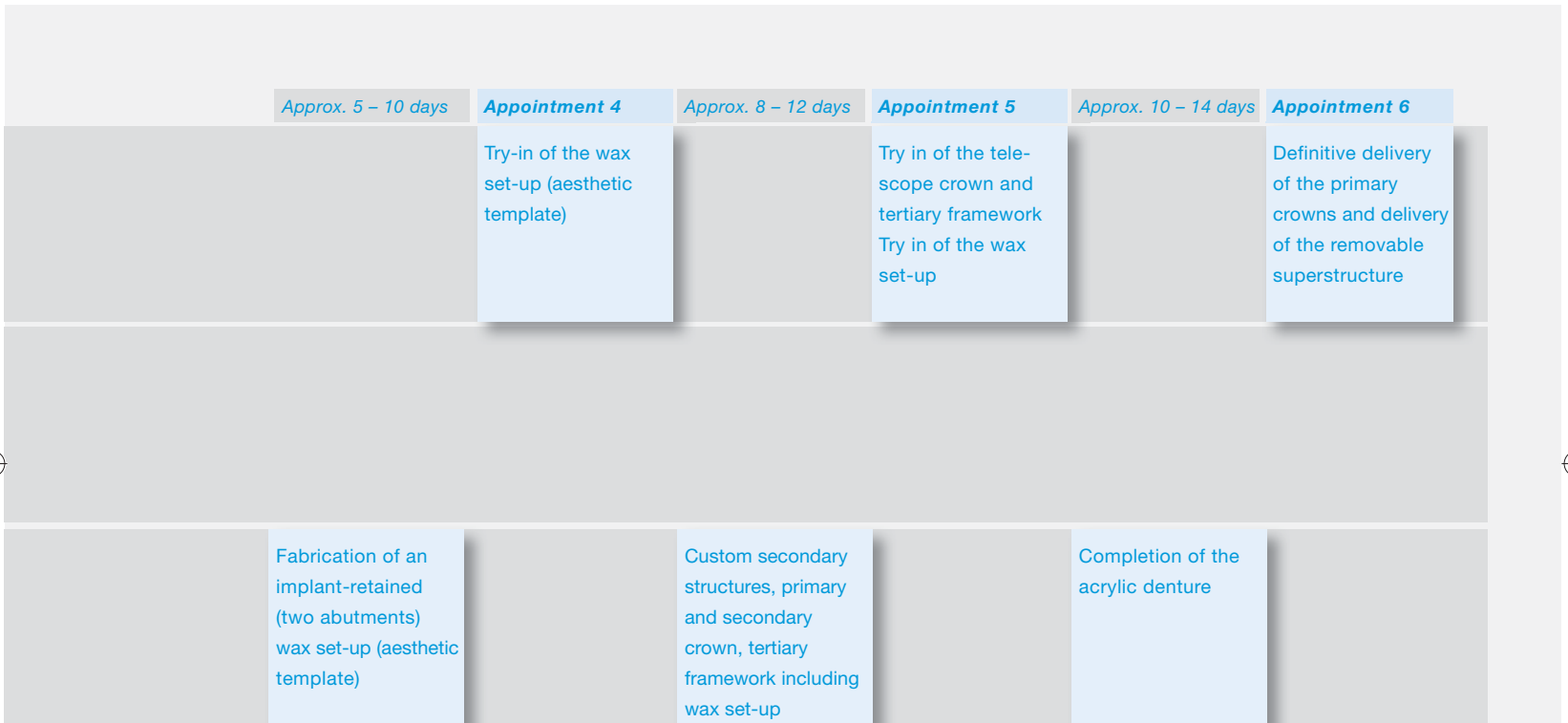
Dental office and laboratory procedures

Procedures for removable superstructures Telescope crowns on four implants

Timeline	Appointment 1	Approx. 5–7 days	Appointment 2	Approx. 3–5 days	Appointment 3
DENTAL OFFICE	Re-entry		Impression (implant/diagnostic), first bite registration, shade taking		Second bite registration with arbitrary hinge axis
IMPLANT LOGISTICS		Ordering implant components, impression		Ordering implant components, superstructures	
LABORATORY		Fabrication of custom impression trays		Cast fabrication, fabrication of implant-supported template (two abutments)	

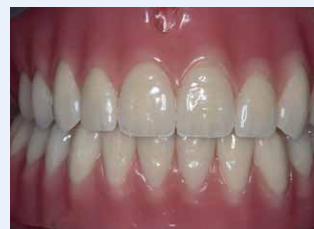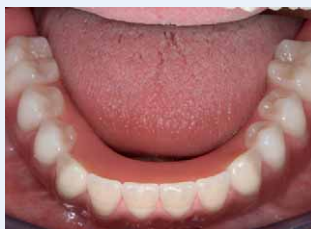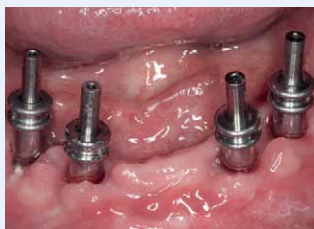EXAMPLES





The timeline between appointments is based on the calculated times for an overdenture supported by four implants with milled telescope crowns. If a different number of implants is used or different fabrication technologies are employed, the timeline may be modified by consultation with the laboratory.

Compared to conventional prosthetics, extra time should be allowed for sourcing and preparing the implant components prior to fabricating the restoration proper.



Find more precious dental alloys at:
www.degudent.com

DeguDent GmbH
Rodenbacher Chaussee 4
63457 Hanau-Wolfgang
Germany

www.degudent.com

DeguDent
A Dentsply International Company